



Erratum

<http://doi.org/10.11646/zootaxa.4111.5.6>

<http://zoobank.org/urn:lsid:zoobank.org:pub:CE43FE22-012C-4535-BD53-97FFF1CC5217>

LAKPA TAMANG, BIKRAMJIT SINHA & SHANTABALA DEVI GURUMAYUM (2015) *Exostoma tenuicaudata*, a new species of glyptosternine catfish (Siluriformes: Sisoridae) from the upper Brahmaputra drainage, northeastern India. *Zootaxa*, 4048(3): 441–445.

These figures are missing from the above-mentioned article.



FIGURE 1. *Exostoma tenuicaudata*, ZSI/APFS 929, holotype, 108 mm SL; India: Arunachal Pradesh, showing: A. Dorsal view; B. Lateral view; C. ventral view.

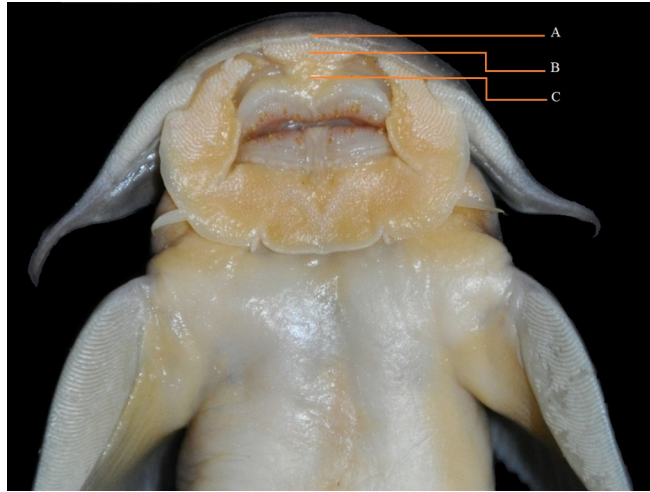


FIGURE 2. *Exostoma tenuicaudata*, ZSI/APFS 929, holotype, 108 mm SL, India: Arunachal Pradesh, showing: A. medial incision on snout tip, B. elliptical plicated pad, and C. fleshy pad.

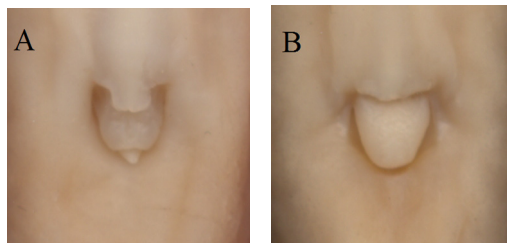


FIGURE 3. Ventral views of anus and external genitalia: of A, *Exostoma tenuicaudata*, female, ZSI/APFS 929, holotype, 108 mm SL, B, male, ZSI/APFS 930, paratype, 90.3 mm SL; India: Arunachal Pradesh.

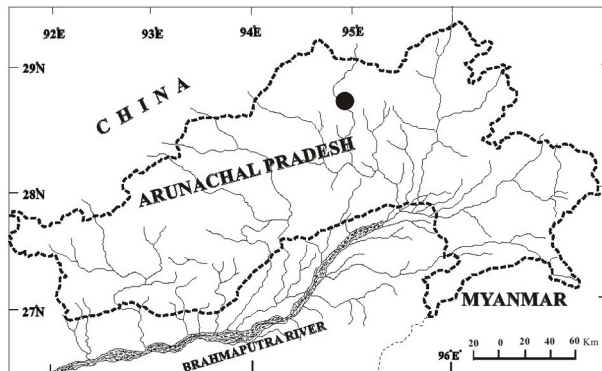


FIGURE 4. Map of Arunachal Pradesh, India, showing the type locality of *Exostoma tenuicaudata*.



FIGURE 5. *Exostoma tenuicaudata*, ZSI/APFS 929, holotype, 108 mm SL, India: Arunachal Pradesh, showing the weakly forked caudal fin, slender caudal peduncle, and the adipose fin not contiguous with the upper caudal procurrent rays.

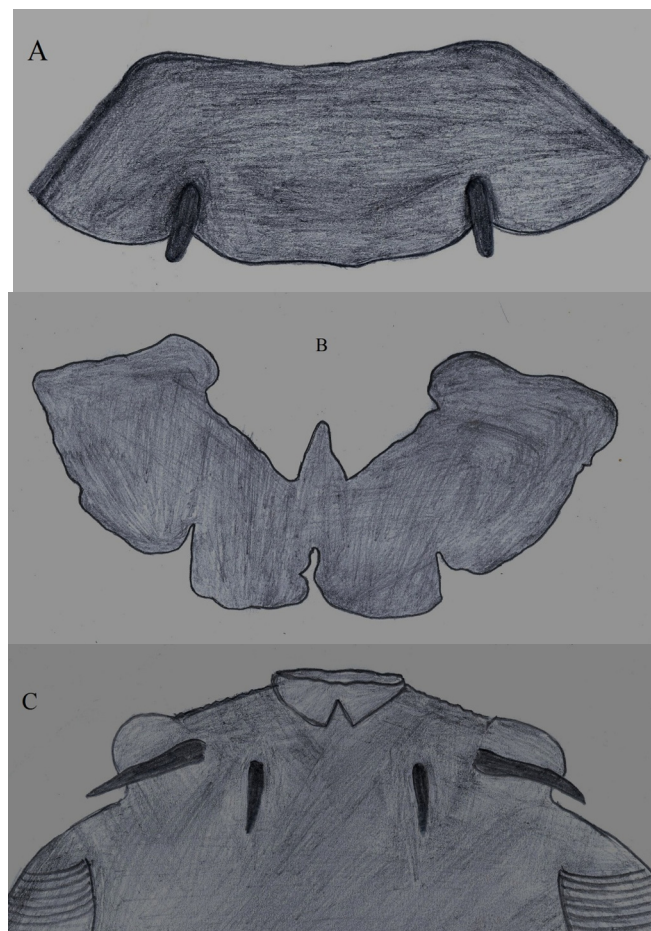


FIGURE 6. Schematic illustrations showing the origin of inner mandibular barbel in *Exostoma* and other glyptosternine genera: A, postlabial fold of lower lip (backview) of *Exostoma tenuicaudata*, ZSI/APFS 929, holotype, 108 mm SL, showing the origin of inner mandibular barbel behind the postlabial fold, not from the isthmus region; B, lower lip postlabial fold (backview) of *Oreoglanis pangenensis*, ZSI/APRC 791, holotype, 76.7 mm SL, showing the absence of inner mandibular barbel on postlabial fold, and C, ventral surface of head of *O. pangenensis*, showing the origin of inner mandibular barbel on isthmus region as similar to that of outer mandibular barbel (lower lip postlabial fold around the mouth is temporarily removed here).